
Anatomical aspects of the celiac artery in lamb

Alina-Valeria BERLEA, Dalma CSIBI, Alexandra IRIMIE, Cristian MARTONOS*,
Irina ROMAN, Aurel DAMIAN

University of Agricultural Sciences and Veterinary Medicine, Faculty of Veterinary
Medicine, 3-5 Mănăştur Street, Cluj-Napoca, Romania
*e-mail: martonosolimpiu@yahoo.com

Abstract

Among different species there are comparable structural characteristics in tissues and organs, but they also have different particularities responsible for certain functions. The components of the cardiovascular system should correspond to the solicitations given by the pressure and blood flow in a particular segment. If the solicitations exceed a particular threshold, the functional adaptation requires supporting morphological changes. The development of the circulatory system in lambs is correlated with the development of the digestive system, the type of nutrition and the characteristics of this species as ruminants. To capture the adaptive changes we resorted to anatomical investigations. The aim of this research was to identify and describe the particularities of the celiac artery in lambs. The study included 15 hybrid Merino lambs, 4-6 months old, sacrificed by the breeder. After removing the skin, the abdominal aorta was identified through stratigraphic dissection. Further on, latex and red coloring substance were injected. This facilitated the following stratigraphic dissection which worked towards the identification of the celiac artery with its collaterals and terminals. We identified that the celiac artery has its origin on the ventral wall of the abdominal in 3 terminal branches: the splenic artery, the hepatic artery and the left gastric artery. All terminal arteries give collaterals to the forestomach. On its trajectory the celiac artery gives only one collateral branch, the caudal phrenic artery. In conclusion, through the collaterals of aorta, near the diaphragm. From the origin, it has a ventro-caudal direction and after 2 cm it separates its terminal branches, the celiac artery is the main blood supplier to the forestomach. Furthermore, the collateral arteries present specific particularities due to the yet incomplete growth of young individuals that were taken into study.

Key words: celiac artery, lamb, visceral collaterals

Introduction

The imaging techniques are important clinical tools, but the study of a cadaver still remains an important and reliable mode in anatomy research and macroscopically description of an organ (Prakash et. al, 2012). More so, by studying a detailed anatomical description of these arteries, it can be beneficial in different fields like experimental surgery, toxicology or pharmacology.

The development of the circulatory system in lambs is correlated with the development of the digestive system, the type of nutrition and the characteristics of this species as ruminants. Celiac trunk variations have been reported often in the literature. The prevalence of normal branching pattern of the coeliac trunk into common hepatic, splenic and left gastric arteries has been reported between 72% and 89.1% (Prakash et. al, 2012).

The aim of this research was to identify and describe the particularities of the celiac artery in lambs.

Material and methods

The study included 15 hybrid Merino lambs, 4-6 months old, sacrificed by the breeder. The abdominal aorta was identified through stratigraphic dissection. The vessel was catheterized with a 18G catheter. An intraluminal lavage with normal saline was performed. Further on, latex and

red coloring substance were injected. This facilitated the following stratigraphic dissection which worked towards the identification of the celiac artery with its collaterals and terminals.

Results and discussion

The celiac artery (*A. celiaca*) detaches from the abdominal aorta close to the diaphragm muscle. From its origin, it takes a ventrocaudal direction and after 2 centimetres it separates in 3 terminal branches: the splenic artery (*A. lienalis*), the hepatic artery (*A. hepatica*) and the left gastric artery (*A. gastrica sinistra*). On its trajectory, the celiac artery gives only one collateral branch, the caudal phrenic artery (*A. phrenicae caudalis*), (Fig.1).

The splenic artery is the first end artery, it enters the spleen through the splenic hilum. In all individuals taken into study, the right ruminal artery (*A. ruminalis dextra*) was identified as the only collateral.

The right ruminal artery is located between the folds of the greater omentum, passes through the right ruminal longitudinal groove (*Sulcus longitudinalis dexter*) in a cranio-caudal direction, through the caudal transvers groove (*Sulcus transversalis*) and reaches the left ruminal longitudinal groove. Here it branches into a dorsal and a ventral end artery which follow the dorsal and ventral coronary grooves. On the whole trajectory it gives dorsal and ventral branches which supply the dorsal and ventral ruminal sacs.

The left gastric artery, because of its caliber, is considered to be the true continuation of the celiac artery. It detaches close to the origin of the splenic artery and it has a ventral direction to the lesser curvature of the abomasum. Its trajectory is in topographic relation with the right side of the rumen and the omasum. As collateral arteries, it presents: the left ruminal artery (*A.ruminalis sinistra*), left gastroepiploic artery (*A.gastroepiploica*), branches for the right cranial part of the rumen and branches for omasum. After giving off collateral arteries, it receives a caudal direction, following the lesser curvature of abomasum, until the pyloric region. Here, it gives terminal branches to supply the lesser curvature and lateral walls of abomasum.

The left ruminal artery has a cranial direction, arrives in the cranial transversal groove and ends in the left longitudinal groove of rumen. Through collateral arteries, it supplies oxygenated blood to the esophagus, reticulum and ruminal left side. We noticed that on the left ruminal surface there are no anastomosis between the left and right ruminal arteries. This characteristic is probably due to the fact that the forestomach is not yet completely developed.

The left gastroepiploic artery is directed caudally to the greater curvature of abomasum, between the *laminae* of greater omentum. Doubled branches are given to the abomasum in a ventro-dorsal direction. Anastomosis between left gastroepiploic branches and left gastric branches are observed. Furthermore, the left gastroepiploic artery and the right gastroepiploic artery undergo anastomosis on the greater curvature of abomasum, between the greater omentum folds.

The hepatic artery is the last terminal artery of the celiac trunk. In some individuals, we observed that its origin is very close to the origin of the left gastric artery. The trajectory has a ventro-lateral direction, to the right, until it reaches the hepatic hilum. It has two terminal arteries: left and right hepatic end arteries. As collaterals, we identified: the right gastric artery (*A.gastrica dexter*) and gastroduodenal artery (*A. gastroduodenalis*), (Fig.2).

The right gastric artery is oriented to the lesser curvature of duodenum, where, in the pyloric region, it gives anastomosis with the left gastric artery. The gastroduodenal artery gives two end arteries: the right gastroepiploic artery and the pancreaticoduodenal artery.

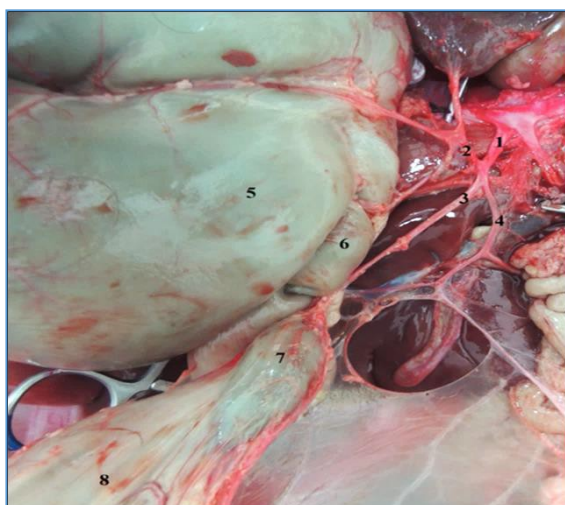


Fig.1. The terminal branches of the celiac artery
 1.celiac artery; 2.splenic artery; 3.left gastric artery; 4.hepatic artery; 5.rumen; 6.reticulum; 7.omasum; 8.abomasum.

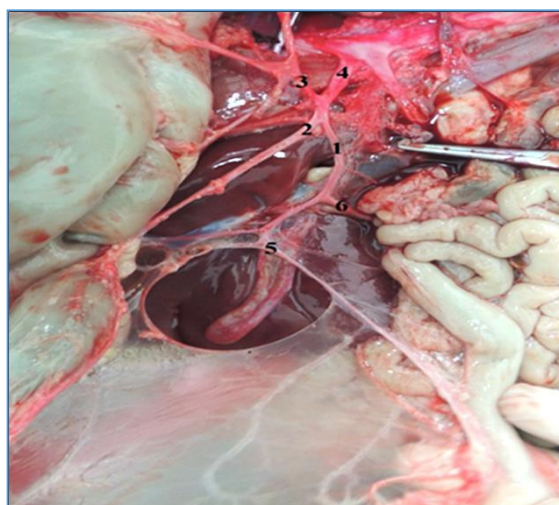


Fig.2. The hepatic artery
 1.hepatic artery; 2.left gastric artery; 3.splenic artery; 4.celiac artery; 5.right gastric artery; 6.gastroduodenal artery.

The origin variations and arteries trajectories for different organs are not only of anatomical interest, but also of clinical and surgical importance (Notkovich, 1956). Although several studies described the celiac trunk and its branches, these blood vessels present several variations at different levels (Niza et al., 2003; Rosa et. al, 2012).

In sheep was reported the presence of a celiacmesenteric trunk, formed by the celiac and cranial mesenteric arteries, (Langenfeld and Pastea, 1977). In humans, the celiacmesenteric trunk is formed by the celiac and the superior mesenteric arteries (Çiçekciabaşı et al., 2005). In one study, they observed a structure formed by the celiac, superior and inferior mesenteric arteries, named the celiac-bimesenteric trunk (Nonent et. al, 2001; Rosa et. al, 2012). In our study, we found these two major arteries are forming a common trunk by mere 0,1 cm.

In a study conducted on goats by Alsafy in 2009, the celiac trunk originated separately from the ventral aspect of abdominal aorta by 0.5 to 1 cm before the origin of cranial mesenteric artery.

The hepatic, splenic and left gastric arteries are the three branches of the celiac trunk in humans. However, Sridhar et al. (2010) reported a hepato-spleno-mesenteric trunk having a common origin from the abdominal aorta. The third branch, the left gastric artery, was directly from the abdominal aorta (Rosa et. al, 2012). But at same time a study related statistics of only approximately 50% of human population, the celiac trunk follows the standard pattern (Chiva et al., 2018).

The author, Alsafy (2009), found several studies that show the celiac trunk and superior mesenteric artery fused with a celiaco-mesenteric trunk, studies conducted on sheep and humans. In humans, one study the left gastric, common hepatic and splenic arteries were found to arise from the celiac trunk in 86% of cadavers. In 76% of cadavers, the origin of the gastric artery was proximal to the bifurcation of the celiac trunk into the common hepatic and splenic arteries (Prakash et. al, 2012).

Conclusions

The variation between a simple celiac artery or a combined celiac mesenteric trunk is high and it can depend not only on species but even on the individual.

In our study the celiac trunk is divided into the three classical branches: the splenic artery, left gastric artery and the hepatic artery.

Furthermore, though the collaterals of its terminal branches, the celiac artery is the main blood supplier for the spleen, forestomach, stomach and liver. However, further investigations are needed through comparison of different sheep breeds.

References

1. Alsafy M.A.M., 2009. Celiac trunk and the variability of its branches in goats. *Journal of Applied Biological Sciences* 3(3):65-70.
2. Chiva L., Magrina J., 2018. Abdominal and Pelvic Anatomy (3–49), doi.org/10.1016/B978-0-323-42878-1.00002-X
3. Çiçekcibaşı A.E., Uysal I.I., Seker M., Tuncer I., Büyükmumcu M., Salbacak A., 2005. A rare variation of the coeliac trunk. *Annals of anatomy*, vol. 187(387-391).
4. Langenfeld M., Patea E., 1977. Anatomical variants of the celiac artery in sheep with special reference to the celiomesenteric arterial trunk. *Anatomischer Anzeiger*, vol. 142 (168-174).
5. Niza MMRE., Vilela C.L., Ferreira AJA., Gonçalves M.S., Pisco J.M., 2003. Irrigação arterial hepática em canídeo. *Revista Portuguesa de Ciências Veterinárias*, vol. 98, no. 546 (69-76).
6. Nonent M., Larroche P., Forlodou P., Senecail B., 2001. Coeliac bimesenteric trunk, anatomic and radiologic description: Case report. *Radiology*, vol. 220, (489-491). PMID:11477258.
7. Prakash T. Rajini, Mokhasi V., Geethanjali B.S., Sivacharan P.V., Shashirekha M., 2012. Coeliac trunk and its branches: anatomical variations and clinical implications. *Singapore Med J. May*;53(5):329-331.
8. Roza M.S., Marinho G.C., Pereira J.A., Salvador-Gomes M., Abidu-Figueiredo M., 2012. Celiac artery with a pulmonary branch in dog: a rare variation, *J. Morphol. Sci.*, vol. 29, no. 4, (253-255).