

The importance of balanced diets administration and vitamin-mineral supplements in puppies and adult dogs

Adrian Maximilian MACRI, , Andrei SZAKACS, Sorana DAINA

University of Agricultural Sciences and Veterinary Medicine, Faculty of Veterinary Medicine, 3-5
Calea Mănăștur street., 400372, Cluj-Napoca, Romania
adimacri@yahoo.com

Abstract

Balanced is a term that may be applied to a diet, ration, or feed having all the required nutrients in proper amount and proportion based upon recommendations of recognized authorities in the field of animal nutrition, such as the NRC, for a given set of physiological requirements. Growth is one period where concerns are frequently reported, as this is one of the most nutritionally demanding life stages, and deficiencies and excesses are manifested quite rapidly. Minerals and vitamins are part of the diet, providing the energy for growth and activity. Individual variation, increased growth rate and/or level of activity may lead to exceeding the daily requirements of minerals and vitamins and thus to disturbance of skeletal growth as a cause of frequently diagnosed orthopedic diseases. Growth rates of young dogs are affected by the nutrient density of the food and the amount of food fed. It is important that puppies be fed to grow at an optimal rate for bone development and body condition rather than at a maximal rate. This study includes 8 dogs all different breeds. The study covers the correction of bone deformities when dogs are given a balanced diet along with vitamin mineral supplements. To obtain the proper information, correct diagnosis and a treatment plan a clinical exam was given to each dog. Radiology reports/images were obtained, as well as blood tests. Once results were collected it is clear supermarket puppy food that does not contain minimum 1.2 - 1.8% CA and 0.8 -1.6% P can lead to bone deformities such as "rickets". Premium dog food and vitamin supplements should be given to small to medium breeds four months to one year old, and larger breeds one and a half to two years old.

Keywords: diet, vitamins, minerals, bone deformities, puppies.

Introduction

Most problems with the bone system occur in animals during the breeding season and that is why it is necessary to advise animal owners on a balanced diet of puppies and cats as soon as possible. Today, a healthy animal should receive all the vitamins and minerals in an adequate proportion if it is fed a balanced and appropriate diet for its species, age and lifestyle (Agar, 2001). The purpose of a diet plan for young animals is to create a healthy adult. The goals are to achieve healthy growth, optimize the immune system and minimize the chances of becoming obese or developing orthopedic conditions. The most common orthopedic conditions due to nutrition are hip dysplasia and osteochondrosis (Wortinger and Burns 2015). Many nutritionists say it is in the animal's best interest to consume commercial food as much as possible. An important aspect to remember is that home-prepared diets have not been analyzed in laboratories to confirm that they are adapted to the stage of life for which they were prepared. However, there are a number of medical reasons why a home-cooked diet may be recommended, such as food allergies (Fascetti and Delaney, 2012). Supplements are usually given to add vitamins and minerals to an animal's diet in the form of tablets, liquid or powder. Today, a healthy animal should receive all the vitamins and minerals in an adequate proportion if it is fed a balanced and appropriate diet for its species, age and lifestyle. These nutrients are needed in very small amounts and supplementing them does not necessarily mean a good thing. For example, the administration of mineral supplements to puppies of large breeds to encourage the growth of the bone system is not necessarily beneficial (Agar, 2001). The growing period is one of the most demanding stages of life from a nutritional point of view and deficiencies or excesses manifest quickly. (Tomsa et al., 1999; McMillan et al. 2006). Both deficiencies and excess minerals (calcium, phosphorus) and vitamins (D and A) can be factors that cause orthopedic conditions including fractures, rickets, osteochondrosis, panosteitis, hip dysplasia.

Minerals and vitamins are part of the diet providing energy for growth and activity. Depending on the individual, a rapid growth rate or an increased level of activity may exceed the daily need for minerals or vitamins affecting skeletal growth and leading to orthopedic conditions (Fascetti and Delaney, 2012). Adult dogs food for maintenance contains a dangerous concentration of calcium for young dogs in the growth phase. The influence of nutrition during different stages of development can be well illustrated by the results of a study done on Great Dane dogs fed a diet containing 3.3% calcium compared to other dogs fed a diet with 1.1% calcium. Administered in 3-17 week old puppies leads to hypophosphatemic rickets and in 6-21 week old puppies osteochondrosis (Hazewinkel, 1999; Fascetti and Delaney, 2012).

Materials and methods

This study aimed to correct some bone deformities by administering balanced diets and vitamin-mineral supplements on a number of 8 dogs of different breeds. The objectives were to perform a clinical examination of the animals, radiographs, blood tests necessary to be able to make a correct diagnosis and appropriate treatment. The clinical examination was accompanied by clinical observation sheets focusing in particular on the anamnesis and food history of the animals. The inspection was done both in the rest and on the movement state, assessing any defective aplomb, limb deformities, limping, possible fractures or asymmetries between limbs or various body regions. The palpation was directed especially towards the deformed regions and towards the level of the costochondral joints. For the biochemical examination, the values of some essential parameters in the diagnosis of rickets were followed, namely alkaline phosphatase, calcium and phosphorus. Blood was collected in the morning and the dogs were not fed before sampling. Radiological examination is recommended because it provides valuable data for confirming or refuting the diagnosis in rickets. On radiological examination, the specific change in rickets is osteopenia, when bone density is obviously low compared to normal being a sign of bone demineralization. Bone deformities can often be observed, more obvious in the long bones, the growth cartilages are modified compared to normal being thickened and the epiphyseal extremities are widened with the appearance of a suction cup. To correct bone deformities diagnosed after clinical examination, radiography and blood tests, 3 vitamin-mineral supplements were used and 5 premium diets available on the market.

Results and discussions

For case 1 (female, Cane Corso, 8 months), at the radiographic examination accentuated radiolucency was observed. Bone deformities with curvature of the femur were present. The distal epiphyses of the femur were enlarged in volume and showed areas of uneven mineralization at this level. The treatment was based on the transition to a balanced diet represented by: premium food 3 approximately 300 g/day; administration of injectable vitamin AD₃E; nutritional supplements No. 1, 1 tablet of 8 g/day. The daily intake of calcium through food and supplements was 4.54g (1.47%) and that of phosphorus was 3.45g (1.12%), the calcium-phosphorus ratio being 1.24: 1. On radiographic examination of the case 2 (female, mixed breed, 6 months), increased radiolucency was observed. At the level of the distal epiphysis of the radius, it is increased in volume with uneven mineralization. The treatment was based on the administration of: 2 ml of vitamin AD₃E at 14 days; administration of vitamin-mineral supplements 2, 2 tablets/day for 6 weeks after which 2 tablets/day for maintenance; premium food 1, about 260 g/day. The daily intake of calcium through food and supplements was 4.84g (1.84%) and that of phosphorus 3.2g (1.21%), the ratio of calcium to phosphorus being 1.52: 1. Regarding case 3 (female, mixed breed, 7 months), the radiographic examination showed an increase in the volume of the distal epiphyses of the radius and ulna

(arrows) with a typical widened appearance, more obvious in the left anterior limb. Treatment consisted in administration of: injectable vitamin AD₃E 2 ml every 14 days; vitamin-mineral supplements 2, 2 tablets/day; premium food 1, about 280 g/day. The daily intake of calcium through food and supplements was 5.12g (1.81%) and that of phosphorus was 3.4g (1.20%), the calcium-phosphorus ratio being 1.54: 1. For case 4 (male, mixed breed, 10 months) on radiographic examination, radiolucency and asymmetric mineralization between different areas of the bone were observed. There are islands of demineralization at the level of the ulna and bone deformities. The epiphyses appear widened, enlarged in volume. The treatment consisted in the administration of: vitamin AD₃E 2 ml every 14 days 1 tablet/day; vitamin-mineral supplement 1, 1 tablet / day; 300 g / day from premium food 3. The daily intake of calcium through food and supplements was 4.54g (1.47%) and that of phosphorus 3.45g (1.12%), the ratio of calcium to phosphorus being 1.3:1. For case 5 (female, mixed breed, 6.5 months) bone deformation and radiolucency were observed on radiographic examination. The distal epiphyses of the radius and ulna have a widened appearance and are enlarged in volume. The treatment was based on: vitamin AD₃E 2 ml every 14 days; approximately 220 g / day of premium food 1; 2 tablets / day of vitamin-mineral supplement 2. The daily intake of calcium through food and supplements was 4.28g (1.92%) and that of phosphorus was 2.8g (1.21%), the ratio of calcium to phosphorus being 1.52: 1. For case 6 (male, Pinscher, 1.5 years) the radiographic examination showed increased radiopacity and the existence of mineral deposits in the distal epiphyses of the tibia and tibia-tarsus-metatarsal joint. The owner administered food for the growing period of an adult dog - premium food 4 and a vitamin-mineral supplement 2. After calculating the daily intake of calcium and phosphorus in the food showed an excess of minerals especially calcium 2.03% (compared to 1.8% maximum recommended). It was thus recommended to switch to a food for small adult dogs, premium food 5 and stop supplementing the food with calcium and phosphorus. For case 7 (female, mixed breed, 7 months) radio transparency was observed on radiographic examination. At the level of the radius and the ulna, bone deformation was observed and at the level of the humerus, areas of bone demineralization. The treatment consisted in the administration of: vitamin AD₃E 1ml every 14 days; vitamin-mineral supplements 1, 1 tablet / day for 6 weeks; premium food 2, about 140 g / day. The daily intake of calcium through food and supplements was 2.56g (1.81%) and that of phosphorus was 1.7g (1.2%), the calcium-phosphorus ratio being 1.5: 1. For case 8 (female, Labrador mixed breed, 2 years) on examination at the rest, a deviation of the distal region of the forelimbs to the side was observed. The metacarpal sesamoid-phalangeal joints appeared thickened. Left hind limb deviated to the side, in the metatarsus-sesamoid-phalangeal region. On palpation of the thorax, the presence of costal rosaries was detected, both on the right and on the left. The treatment consisted of the administration of: vitamin AD₃E 2 ml every 14 days; premium food 1, about 280 g / day; 4 tablets of vitamin-mineral supplement 2. The daily calcium intake was 1.77% and the phosphorus intake of 1.42%, the calcium-phosphorus ratio being 1.24:1.

As shown in Figures 1, alkaline phosphatase was increased in all patients studied with a minimum of 223, 8 U / l and a maximum of 438 U / l, calcium was below the normal limit of 11 mg/dl in 7 of the patients with a minimum of 6.5 mg/dl and a maximum of 8.9 mg/dl (Figure 2). One case, no. 6 showed a value higher than 12.8. This patient was 1.5 years old and was still fed premium chicken feed and was receiving vitamin and mineral supplements.

Phosphorus values were below the normal limit in 4 of the patients (case 1,2,4,5) with a minimum of 2.1 mg / dl and a maximum of 2.5 mg / l. Case 3 and 6 recorded values above the maximum allowed limit and case 8 had a value of 3.1 mg / l within the normal limits (Figure 3).

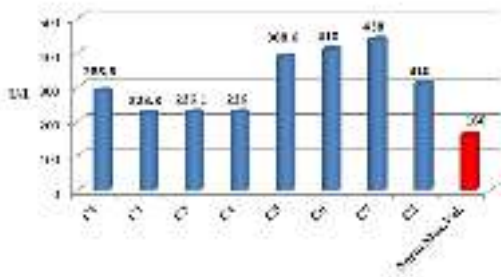

Fig.1. Alkaline phosphatase values

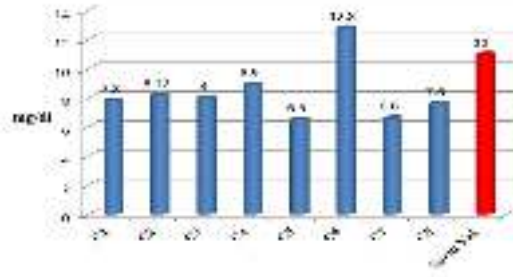


Fig.2. Calcium values

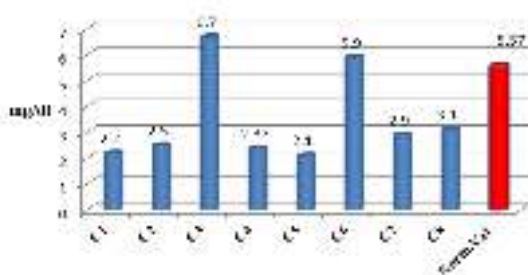


Fig.3. Phosphorus values

The use of supermarket food in the diet of growing puppies or other diets that do not contain 1.2-1.8% Ca as well as 0.8-1.6% P in their structure, as seen in the cases investigated by us, can lead to the appearance of typical bone changes for rickets.

In a study conducted in 1992 by Roudebush and Cowell, they showed that 89 and 93% of home-cooked diets used in dogs and cats were not complete and balanced).

Another study in which owners administered home-prepared diets for their animals for a period of 30 days demonstrated the following: home-prepared diets were evaluated and compared with recommendations for nutritional profiles given by AAFCO (the Association of American Feed Control Officials) (Streiff et al., 2002). 35 of the diets had inadequate levels of calcium, phosphorus, potassium, zinc, copper and vitamin A and E compared to AAFCO recommendations (Fascetti Delaney J. S., 2012). In 2005, Lauten et al. evaluated 49 maintenance diets and 36 for breeding in dogs and cats. These were prepared according to books that veterinarians often recommend. Comparing the AAFCO standards for the animal's life stage, 55% had inadequate amounts of protein, 64% of vitamins and 86% of minerals. In 2012, Fascetti and Delaney also showed in a study how 4 cats of close age who received colostrum and commercial milk replacement formula and after weaning received a homemade diet based on 60% minced beef, chicken and turkey and 40% vegetables (carrots, green leaves, broccoli, turnip, celery roots). From time to time they also received boiled bones, showing signs of lameness from 2.5 months. Cats had a normal appetite and were energetic. On blood tests they came out normal except for the alkaline phosphatase which was high. The radiographs showed a severe bone rarefaction with decreased

bone opacity and fractures in the femur, ilium and the possibility of compression in the sacral vertebrae. At the gastrointestinal level, bone fragments were found.

Conclusions

The diet used to feed the investigated animals was either unknown or came from supermarkets, and on their label was not found the level of calcium and phosphorus contained. It is obvious that these products do not comply with the Ca / P ratio necessary for the development of the dog's bone system, and the clinical manifestations, as well as the paraclinical examinations performed, confirm the nutritional imbalances. It is also good to recommend a calculation of the total amount of calcium administered daily when using the diet in the supermarket (which has noted on the packaging especially the calcium and phosphorus content) or premium category, to avoid excess Ca and P, which in turn can lead to ectopic calcium deposits in the body.

References

5. Agar S., 2001. Small Animal Nutrition, 1st Edition, Butterworth-Heinemann, Pag 33 -81
6. Fascetti, A. J., J. S. Delaney, 2012, Applied Veterinary Clinical Nutrition, Wiley-Blackwell, an imprint of John Wiley & Sons INC pag 98-150.
7. Hazewinkel, H.A.W., I. Schoenmakers, R.C. Nap, 1999, Considerations in feeding young dogs of different genetic backgrounds and life stages. Purina Nutrition Forum Proceedings, St. Louis, 88.
8. Lauten, S.D., T.M. Smith, C.A. Kirk, 2005, "Computer analysis of nutrient sufficiency of published home-cooked diets for dogs and cats" (abstract). Journal of Veterinary Internal Medicine 19: 476.
9. McMillan, C.J., D.J.Griffon, S.L. Marks, G.E.Mauldin, 2006, Dietary-related skeletal changes in a Shetland sheepdog puppy, J Am Anim Hosp Assoc 42(1):57-64.
10. Streiff, E.L., B. Zwischenberger, R.F. Butterwick, 2002, A comparison of the nutritional adequacy of homeprepared and commercial diets for dogs. Journal of Nutrition 132: 1698S–1700S.
11. Roudebush P., Cowell C.S., 1992. Results of a Hypoallergenic Diet Survey of Veterinarians in North America with a Nutritional Evaluation of Homemade Diet Prescriptions. Veterinary Dermatology, Vol.3, Issue 1, 23-28.
12. Tomsa, K., T. Glaus, B. Hauser, 1999, Nutritional hyperparathyroidism in six cats. Journal of Small Animal Practice 40(11): pag 533–539.
13. Wortinger, Ann, M. K. Burns, 2015, Nutrition and Disease Management for Veterinary Technicians and Nurses, by John Wiley & Sons, Inc. pag. 25-228.