

IDENTIFICATION OF CORONAVIRAL ANTIBODIES AND CORONAVIRUS - SPECIFIC ANTIBODY COMPLEXES IN ASCITES FLUID OF CATS DIAGNOSTICATED WITH FELINE INFECTIOUS PERITONITIS

Cristina HORHOGEA^{*1}, Ivona LAIU¹, Sophie Le PODER², M. CARP-CĂRARE¹,
Cristina RÎMBU¹, C. CARP-CĂRARE¹

¹*University of Agricultural Sciences and Veterinary Medicine Iași, Romania*

²*Ecole Nationale Vétérinaire d'Alfort , France*

Received Novembre 19, 2010

ABSTRACT - Feline infectious peritonitis (FIP) is an infectious lethal cat diseases, produced by a mutant feline coronavirus (feline infectious peritonitis virus), which is manifested in two clinical forms. Dry form may go unnoticed or be confused with other diseases. Wet form, however, evolve with ascites fluid accumulation, its appearance being correlated with end-stage of the disease. Research has pursued the efficiency of direct immunofluorescence test for the identification of coronavirus - anticoronavirus antibody complexes in ascites fluid. Nine ascites fluid samples, obtained from cats aged between 1,7 months and 13 years, diagnosed with feline infectious peritonitis, were analyzed. The antibody titers were assessed using indirect immunofluorescence on pig kidney (PK) cell cultures infected with TGEV, on three samples, titres ranging from 1/25 and 1/625. All nine ascites fluid samples tested by direct immunofluorescence for detection of coronavirus specific antibodies complexes were positive. In images obtained with UV

in microscopy, fluorescence being seen in the macrophages under the form of a ring arranged on the periphery of the cell membrane and fluorescence localized intracellularly, probably internalized immune complexes. The results lead us to recommend the use of this test for FIP rapid diagnostic.

Key words: Coronavirus; Peritonitis; Immunofluorescence; Ascites; Complex.

REZUMAT - Identificarea complexelor specifice coronavirus – anticorpi anticoronavirali în lichidul ascitic la pisicile diagnosticate cu peritonită infecțioasă felină. Peritonita infecțioasă felină (PIF) este o boală letală a pisicilor, produsă de o mutantă a coronavirusului enteric felin (virusul peritonitei infecțioase feline), care se manifestă sub două forme clinice. Forma uscată poate trece neobservată sau poate fi confundată cu alte maladii. Forma umedă, în schimb, evoluează cu acumularea lichidului ascitic,

* E-mail: rebegeacristina@yahoo.com

apariția acestuia corelându-se cu stadiul final al bolii. Cercetările au urmărit eficiența testului de imunofluorescență directă, utilizat pentru identificarea complexelor coronavirus – anticorpi anticoronavirus în lichidul ascitic. Au fost analizate nouă probe de lichid ascitic, obținute de la pisici cu vârsta cuprinsă între 1,7 luni și 13 ani, diagnosticate cu peritonită infecțioasă felină. Titrul de anticorpi a fost evaluat, utilizând imunofluorescența indirectă pe culturi celulare renale de porc, infectate cu TGEV, pe trei probe, titrul variind între 1/25 și 1/625. Toate cele nouă probe de lichid ascitic, testate prin imunofluorescența directă pentru depistarea complexelor coronavirus – anticorpi specifici, au fost pozitive, ceea ce ne îndreptățește să recomandăm utilizarea testului pentru diagnosticul rapid în PIF. În imaginile obținute la microscopul cu UV s-au observat celule (macrofage) cu fluorescența dispusă sub formă de inel la periferia membranei celulare. De asemenea, au putut fi observate celule la care fluorescența este localizată intracelular, probabil complexele imune internalizate.

Cuvinte cheie: coronavirus; peritonită; imunofluorescență; ascită; complexe.

INTRODUCTION

Feline infectious peritonitis (FIP) is a fatal disease of cats caused by a coronavirus, feline infectious peritonitis virus (FIPV), able to infect domestic and wild cats of all ages, although younger ones and those over 14 years seem to be most susceptible. FIPV is a part of *Coronaviridae* family that comprised two genera, *Coronavirus* and *Torovirus*, displaying similarities in morphology, genomic organization, and gene expression (Gorbalenya *et al.*, 2008). Regarding genetic and serological

properties, there are three phylogenetic groups inside *Coronavirus* genus (Enjuanes *et al.*, 2000). Feline coronavirus (FCoV) is a member of antigenic group I, beside human coronaviruses (HCoV) 229E and NL63, porcine transmissible gastroenteritis virus (TGEV) and canine coronavirus (CCoV) (Erles *et al.*, 2003; Snijder *et al.*, 2003). FIPV is considered to be a very pathogen variety of enteric feline coronavirus.

Characteristic for the wet form of the disease is the accumulation of fluid in different cavities, according to the affected blood vessel. Ascites fluid appearance is correlated with end-stage disease. According to the literature FIPV enters target macrophage/monocytes, binds to the cell surface, being internalized by a clathrin and caveolae independent and dynamin dependent endocytosis (Van Hamme *et al.*, 2008). Dewerchin and coworkers (Dewerchin *et al.*, 2008) added and suggested that viral antigen-antibody complexes in FIP were not internalized through any of the previously described pathways, the process being independent from phosphatases and tyrosine kinases, but depending on serine/threonine kinases.

Virological diagnosis lasts 48 hours and is very expensive. A faster method of diagnosis would be welcome. There are commercial kits, but not very cheap and therefore a simpler method would be more efficient.

Since the ascites fluid may contain viral antigens and specific antibodies that can be detected as a complex, research has pursued the

IMMUNODIAGNOSTIC IN FIP

possibility of highlighting them using direct immunofluorescence test.

MATERIALS AND METHODS

Research was carried out on samples from nine cats diagnosed with FIP aged 1,7 months to 13 years, seven being the common race, a Burmese and a Russian Blue. Regarding gender distribution, three were males and six females.

To highlight the complex coronavirus - anticoronavirus antibodies, were tested by direct immunofluorescence (DIF) nine peritoneal effusion samples, identification of feline coronavirus previously been accomplished by the RT-PCR.

To identify anticoronaviral antibodies, indirect immunofluorescence reaction (IIF) on pig kidney cell culture (PK) infected with TGEV and incubated 48 h at 37°C was used. Cells were fixed with ethanol, washed, after which dilutions of ascites fluid were added and incubated for 60 minutes at 37 °C. After further washes, fluorescein isothiocyanate-conjugated goat anti-feline antiserum (Jackson Immunoresearch) was added and incubated for 60 minutes at 37°C. Fluorescence was observed using IX51 Olympus inverted microscope. The titer was expressed as the highest dilution (1:25, 1:125, 1: 625, 1: 3,125, 1: 1,6000) at which fluorescence was detectable.

In order to identify coronavirus – anticoronaviral antibody complexes direct immunofluorescence reaction was used, ascites fluid was centrifuged at 3000 rpm for 10 minutes and of the cells deposit, a smear was done. After fixation for 10 minutes and washing with ethanol, fluorescein isothiocyanate-conjugated goat anti-feline antiserum (Jackson Immunoresearch) was added and

incubated for 60 minutes at 37°C. Fluorescent complexes were observed using IX51 Olympus inverted microscope.

RESULTS AND DISCUSSION

Using direct immunofluorescence reaction, all nine samples peritoneal effusions were positive (*Table 1*), demonstrating that the animals were exposed to feline coronavirus.

The images obtained at the immunofluorescence revealed a lot of cells (macrophages) with fluorescence with ring shape arranged on the periphery of the cell membrane (*Fig. 1*). Also, there can be observed cells without external green ring, but with fluorescence inside, perhaps internalized complexes.

Three of these samples were previously tested by indirect immunofluorescence for antibody titer determination, being positive, with values of 1/25, 1/125 and 1/625 (*Fig. 2, 3*).

As you can see, the immunofluorescence reaction can be used for detection of specific antibodies, viral antigens or immune complexes. Given that ascites fluid is an inflammatory exudate, macrophages, target cells for feline infectious peritonitis virus are present, it can be considered an extremely precious material for pathological diagnosis. Also, abdominal effusion may present large amounts of antibodies, coupled as complex with the coronavirus.

Table 1 - Cases presented at consultation, diagnosed with FIP

No. Crt.	Specie	Breed	Sex	Age	Anamnesis	Results of DIF	Results of IIF
1	Feline	Common	Male	10 years	FIP wet form: anorexia, fever, ascites fluid accumulation in the abdominal cavity	+	1/125
2	Feline	Common	Female	13 years	FIP wet form: ultrasound examination: fluid with increased cellularity, tumors on the stomach, pancreas, intestine, mesentery, fibrin, ascites fluid.	+	1/625
3	Feline	Birman	Female	10 years	FIP, wet form: fluid, with increased turbidity in the abdomen and chest, on X-rays were observed lung opacification areas, abdominal type breath.	+	1/25
4	Feline	Russian Blue	Female	2 years	FIP, wet form: accumulation of fluid in the abdomen and chest, associated with respiratory problems	+	-
5	Feline	Common	Female	1,7 months	FIP, wet form: accumulation of fluid in the abdomen	+	-
6	Feline	Common	Male	2 years	FIP, wet form: clinical respiratory signs, conjunctivitis, ascites fluid in large quantities, very filante, yellow, P-8, 1g/dl	+	-
7	Feline	Common	Female	2 years	FIP, wet form	+	-
8	Feline	Common	Male	1,5 years	FIP, wet form hepatitis, nephritis, ascites fluid in small quantity, very pale mucous	+	-
9	Feline	Common	Female	5 months	FIP, wet form: anorexia, fever, altered echogenicity of liver with presence of nodules, swollen blood vessels, fluid filante in small quantity.	+	-

IMMUNODIAGNOSTIC IN FIP

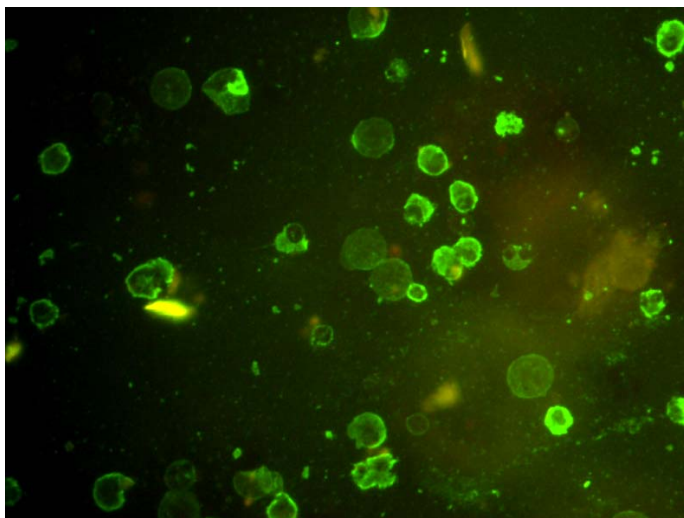
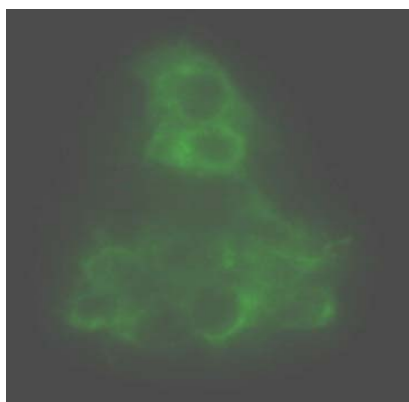


Figure 1 – Immunofluorescence on ascites fluid, x20



**Figure 2 – PK cells infected with TGEV
*Cytoplasmatic fluorescence, x20***



**Figure 3 – PK cells infected with TGEV
*Negativ control, x20***

It is known that is practical impossible to make difference between feline enteric coronavirus (FCoV) and feline infectious peritonitis virus (VPIF), because the latter is a mutant of the first, the conditions in which the mutation occurs being unknown, just suspected. But, only FIPV has the ability to replicate in macrophages.

The acquisition of macrophage tropism appears to be an essential step in the transformation of an FCoV to an FIPV and from a largely non-pathogenic and localized enterocyte pathogen to a highly virulent and systemic monocyte/macrophage pathogen. The relationship between virulence and macrophage/monocyte

tropism has been firmly established in the literature (Pedersen, 2009).

The presence and titre of serum anticoronavirus antibodies have no clinical value if they are not related with specific symptoms, but may raise questions if they are identified. Occurrence of ascites in cats is related to about 50% of them with the suspicion of feline infectious peritonitis evolution.

Perhaps, the method we described may be useful to shorten the period to confirm or refute the diagnosis of feline infectious peritonitis. It is very important for practitioners who must adopt a certain therapeutic behavior depending on the results.

CONCLUSIONS

Nine ascites fluid samples, obtained from cats with ages between 1,7 months and 13 years, diagnosed with feline infectious peritonitis, were analyzed.

The antibody titers were assessed using indirect immunofluorescence on pig kidney cells infected with TGEV, in three samples, titres ranging from 1 / 25 and 1 / 625;

All nine ascites fluid samples tested by direct immunofluorescence for detection of coronavirus - specific antibodies complex on the surface or inside macrophages were positive.

The results lead us to recommend the use of direct immunofluorescence test for rapid diagnosis of the PIF.

Acknowledgments. We thank Ph.D Prof. Gheorghe Solcan, Ph.D Mihai Musteață from Intern Clinics and Ph.D Sorin Pașca for the cases provided. Materials, reagents and kits used were purchased under the project type IDEI, code 1129/2008 (*Developing a method for identification of coronaviruses naturally infected cats that distinguishes between the canine and feline genotype*), funded by the Executive Unit for Financing Higher Education and Educational Research (UEFISCSU), Romania.

REFERENCES

- Dewerchin H.L., E. Cornelissen, E. Van Hamme, K. Smits, B. Verhasselt, H.J. Nauwynck, 2008 - Surface-expressed viral proteins in feline infectious peritonitis virus-infected monocytes are internalized through a clathrin- and caveolae-independent pathway. *J. Gen. Virol.* 2008; 89: 2731-40.
- Enjuanes L., D. Brian, D. Cavanagh, K. Holmes, M.M.C. Lai, H. Laude, P. Masters, P. Rottier, S. Siddel, W.J. Spaan, F. Taguchi, P. Talbot, 2000 - Family *Coronaviridae*. In: Van Regenmortel, M.H.V., Fauquet, C.M., Bishop, D.H.L., Carstens, E.B., Estes, M.K., Lemon, S.M., Maniloff, J., Mayo, M.A., McGeoch, D.J., Pringle, C.R., Wickner, R.B. (Eds) - *Virus Taxonomy, Classification and Nomenclature of Viruses*, Academic 339 Press, New York, pp. 835-849.
- Erles K., C. Toomey, H. Brooks, J. Brownlie, 2003 - Detection of a group 2 coronavirus in 345 dogs with canine infectious respiratory disease. *Virology* 310, 216-223.

IMMUNODIAGNOSTIC IN FIP

- Gorbalenya A. E., L. Enjuanes, J. Ziebuhr, E.J. Snijder, 2006** - Nidovirales: evolving the 354 largest RNA virus genome. *Virus Res.*, 117, 17-37.
- Pedersen Niels C., 2009** - A review of feline infectious peritonitis virus infection:1963-2008, *Journal of Feline Medicine and Surgery*, 11, 225-258.
- Snijder E.J., P.J. Bredenbeek, J.C. Dobbe, V. Thiel, J. Ziebuhr, L.L. Poon, Y. Guan, M. Rozanov, W.J. Spaan, A.E. Gorbalenya, 2003** - Unique and conserved features of genome and 401 proteome of SARS-coronavirus, an early split-off from the coronavirus group 2 lineage. *J. Mol. Biol.*, 331, 991-1004.
- Van Hamme E., H.L. Dewerchin, E. Cornelissen, B. Verhasselt, H.J. Nauwynck, 2008** - Clathrin - and caveolae-independent entry of feline infectious peritonitis virus in monocytes depends on dynamin. *J. Gen Virol.*, 89: 2147-56.